

EXTRACT FROM CLINICAL STUDY (in progress)

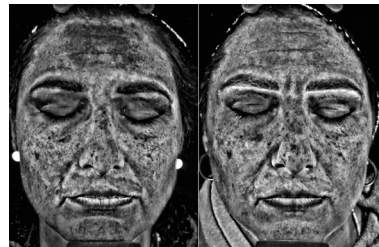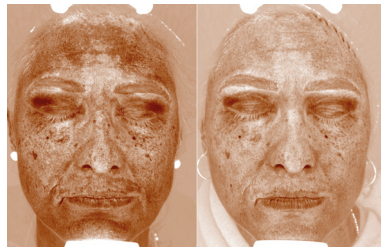
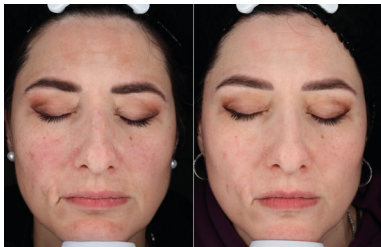Observational study on the use of Agex depigmenting Serum Spot combined with Q-switched laser for the treatment of melasma

Dr. G. Scarcella

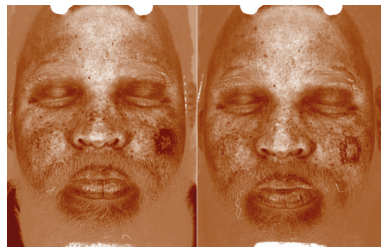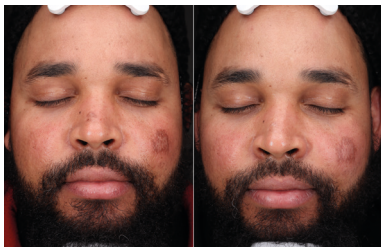Protocol

The protocol involved treatment with Q-Switched laser sessions (a minimum of 3 sessions to a maximum of 6) at 3/5 week intervals.

Between sessions, application of Agex Serum Spot twice a day.



PATIENT D: Melasma forehead and upper lip skin. Photographs taken with CANFIELD's CanfieldVISIA Facial Imaging System (polarised VISIA, UV spots and brown spots). Before treatment and after the third laser session.



PATIENT F: Post-inflammatory hyperchromia of a probable melasma of the skin of the nasal dorsum and left cheekbone. VISIA photos (spots and brown spots). Before and after two laser sessions. Before and 1 month after the fourth laser session.

